

Melissa L. Siew, Arjan B. te Pas, Megan J. Wallace, Marcus J. Kitchen, Robert A. Lewis, Andreas Fouras, Colin J. Morley, Peter G. Davis, Naoto Yagi, Kentaro Uesugi and Stuart B. Hooper

J Appl Physiol 106:1487-1493, 2009. First published Mar 26, 2009;
doi:10.1152/jappphysiol.91591.2008

You might find this additional information useful...

Supplemental material for this article can be found at:

<http://jap.physiology.org/cgi/content/full/91591.2008/DC1>

This article cites 34 articles, 14 of which you can access free at:

<http://jap.physiology.org/cgi/content/full/106/5/1487#BIBL>

Updated information and services including high-resolution figures, can be found at:

<http://jap.physiology.org/cgi/content/full/106/5/1487>

Additional material and information about *Journal of Applied Physiology* can be found at:

<http://www.the-aps.org/publications/jappl>

This information is current as of May 13, 2009 .

Positive end-expiratory pressure enhances development of a functional residual capacity in preterm rabbits ventilated from birth

Melissa L. Siew,¹ Arjan B. te Pas,² Megan J. Wallace,¹ Marcus J. Kitchen,³ Robert A. Lewis,^{3,4} Andreas Fouras,⁵ Colin J. Morley,² Peter G. Davis,² Naoto Yagi,⁶ Kentaro Uesugi,⁶ and Stuart B. Hooper¹

¹Department of Physiology, ³School of Physics, ⁴Monash Centre for Synchrotron Science, and ⁵Division of Biological Engineering, Monash University, Melbourne; and ²Neonatal Research, Royal Women's Hospital, Parkville, Victoria, Australia; and ⁶Spring-8/JASRI, Sayo, Hyogo, Japan

Submitted 2 December 2008; accepted in final form 21 March 2009

Siew ML, te Pas AB, Wallace MJ, Kitchen MJ, Lewis RA, Fouras A, Morley CJ, Davis PG, Yagi N, Uesugi K, Hooper SB. Positive end-expiratory pressure enhances development of a functional residual capacity in preterm rabbits ventilated from birth. *J Appl Physiol* 106: 1487–1493, 2009. First published March 26, 2009; doi:10.1152/jappphysiol.91591.2008.—The factors regulating lung aeration and the initiation of pulmonary gas exchange at birth are largely unknown, particularly in infants born very preterm. As hydrostatic pressure gradients may play a role, we have examined the effect of a positive end-expiratory pressure (PEEP) on the spatial and temporal pattern of lung aeration in preterm rabbit pups mechanically ventilated from birth using simultaneous phase-contrast X-ray imaging and plethysmography. Preterm rabbit pups were delivered by caesarean section at 28 days of gestational age, anesthetized, intubated, and placed within a water-filled plethysmograph (head out). Pups were imaged as they were mechanically ventilated from birth with a PEEP of either 0 cmH₂O or 5 cmH₂O. The peak inflation pressure was held constant at 35 cmH₂O. Without PEEP, gas only entered into the distal airways during inflation. The distal airways collapsed during expiration, and, as a result, the functional residual capacity (FRC) did not increase above the lung's anatomic dead space volume (2.5 ± 0.8 ml/kg). In contrast, ventilation with 5-cmH₂O PEEP gradually increased aeration of the distal airways, which did not collapse at end expiration. The FRC achieved in pups ventilated with PEEP (19.9 ± 3.2 ml/kg) was significantly greater than in pups ventilated without PEEP (-2.3 ± 3.5 ml/kg). PEEP greatly facilitates aeration of the distal airways and the accumulation of FRC and prevents distal airway collapse at end expiration in very preterm rabbit pups mechanically ventilated from birth.

phase contrast X-ray imaging; plethysmography; resuscitation

AT BIRTH, THE AIRWAYS MUST be cleared of liquid to allow the entry of air and the onset of pulmonary gas exchange (7, 9, 24). This process is closely associated with major changes in cardiopulmonary physiology that are essential for the transition to air breathing after birth, including a large increase in pulmonary blood flow (5, 10). Although airway liquid clearance is thought to result from an osmotic gradient induced by Na⁺ reabsorption (12, 24), resulting in liquid movement into the interstitial tissue compartment (3), hydrostatic pressures generated by inspiration may also play a significant role (11). As Na⁺ reabsorptive mechanisms are immature and potentially nonfunctional in very preterm infants (1, 24, 34), transpulmonary hydrostatic pressures may be critical for airway liquid clearance in preterm infants.

Infants born very preterm have immature lungs that are surfactant deficient, partially liquid filled, and prone to collapse at end expiration. As a result, very preterm infants commonly require assisted ventilation after birth, which can be required for many weeks (29). Little is known about procedures that facilitate airway liquid clearance and uniform lung aeration at birth, particularly in very preterm infants who commonly suffer from airway liquid retention. Although ventilating very preterm infants with a positive end-expiratory pressure (PEEP) has many advantages (6, 21, 26, 30), particularly in enhancing oxygenation and preventing airway collapse at end expiration (20, 23), its effects on lung aeration at birth are unknown. If airway liquid clearance is mainly regulated by hydrostatic pressures in the immature lung (11), the application of PEEP at birth may enhance airway liquid clearance and uniform lung aeration.

Phase contrast X-ray imaging (PCI) can be used to observe and measure the temporal and spatial pattern of lung aeration from birth in newborn rabbit pups (11, 19). PCI exploits the refractive index differences between air and water to produce contrast of air/liquid boundaries in the lung (15–19, 28, 35). As a result, the liquid-filled fetal lung only becomes visible following the entry of air after birth, providing high-resolution images of all air-filled structures, including alveoli (11). This imaging technique is ideal for measuring the temporal and spatial pattern of lung aeration and has been used to observe the air/liquid interface as it moves distally into the terminal airways of spontaneously breathing rabbit pups (11). These studies demonstrated that the distal movement of the air/liquid interface only occurred during inspiration, suggesting that transepithelial hydrostatic pressures are intimately involved in this process. In this study, we hypothesized that PEEP, applied from the first inflation after birth, enhances airway liquid clearance and uniform lung aeration in very preterm rabbit pups. To investigate this, we imaged lung aeration in ventilated, very preterm rabbit pups from birth, in the presence and absence of PEEP, and simultaneously measured changes in lung gas volumes using plethysmography.

METHODS

Experimental procedure. All experiments were approved by Spring-8 and Monash University's School of Biomedical Science's Animal Ethics Committees. Studies were conducted in experimental hutch 3 of beam line 20B2, in the Biomedical Imaging Centre at the Spring-8 synchrotron in Japan.

At 28 days gestational age (term = 32 days), pregnant New Zealand White rabbits ($n = 8$) were anesthetized using propofol (Rapinovet; intravenous; 12 mg/kg bolus) and intubated, and anesthe-

Address for reprint requests and other correspondence: S. B. Hooper, Dept. of Physiology, Monash Univ., Melbourne, Vic 3800, Australia (e-mail: stuart.hooper@med.monash.edu.au).

sia was maintained by isoflourane inhalation (1.5–4%). Pups were exteriorized by caesarean section, sedated with sodium pentobarbitone (Nembutal; 0.1 mg ip), intubated (via a tracheotomy) with an 18G tube, and delivered. Spontaneous breathing was prevented before imaging started by occluding the endotracheal tube. Immediately after delivery, the pup was placed vertically in a water-filled (40°C) plethysmograph with the head out and positioned so the chest was in the path of the X-ray beam. The endotracheal tube was connected to a small-animal ventilator (SAR-830/P; CWE), and ventilation commenced with the onset of imaging (~1–2 min after delivery). Pups were ventilated with air using a peak inflation pressure (PIP) of 35 cmH₂O and 16 inflations per minute with a 1-s inflation time. They were randomly allocated to either no PEEP (0PEEP) or a PEEP of 5 cmH₂O (5PEEP). It was not possible to alter the PEEP or PIP settings during imaging, as the ventilator could not be controlled remotely. All pups were ventilated and imaged for 7–10 min after birth and then killed with sodium pentobarbitone (Nembutal; 100 mg/kg ip).

Plethysmography. Lung air volume changes were measured from birth using a custom-made water-filled plethysmograph (14), composed of an upright (height 12 cm), cylindrical (diameter 32 mm), water-filled chamber, sealed at the top by a rubber diaphragm, and open to atmosphere via a vertical water column. The pup's head was exteriorized from the chamber via a hole in the diaphragm, which formed a water-tight seal around the pup's neck. Changes in thoracic volume due to air inhalation caused water to move between the chamber and water column. The resulting pressure changes were measured using a pressure transducer (DTX Plus TNF-R; Becton Dickinson) and recorded digitally (Powerlab, ADInstruments, Sydney, Australia). The plethysmograph was calibrated by injecting 1 ml of water before each experiment.

PCI. PCI was used to image air entry into the lungs from birth to investigate the rate and spatial pattern of lung aeration. Simultaneous plethysmography measured changes in gas volumes, although this could also be obtained from the images (14). Details describing the imaging procedures have been reported previously (11, 17, 19). Briefly, the X-ray energy was 24 keV, the pups were 2.0 m upstream of the detector (EMCCD, C9100–02), and a 50-ms exposure time and a 1-s inflation time were used to minimize motion blur. Image acquisition and ventilation were synchronized with inflation onset triggering a sequence of six images (300-ms intervals). A preobect shutter prevented radiation exposure between images, and the timing of image acquisition was recorded digitally, simultaneously with the plethysmograph recording.

Data and statistical analysis. All lung gas volumes were adjusted for body weight. Functional residual capacity (FRC) was determined as the lung gas volume at end expiration, and tidal volume (V_T) as the volume at end inflation minus the postinflation FRC (expired gas volume). FRC and V_T values were an average of three inflations and measured at inflation 5 ± 1 (i.e., average of inflations 4–6), inflation 20 ± 1, and at every 20 ± 1 inflations for 120 inflations.

The anatomic dead space (ADS) volume was determined from the images as the volume of air in the lung at the first appearance of a fine speckle within the image. Speckling is caused by the focusing effects of multiple overlying air/liquid boundaries in projection, which act as a series of aberrant compound refractive lenses (11, 16, 17, 19). Speckle appears in the image when air reaches the small terminal airways and exactly corresponds in timing with a marked inflection in the lung pressure-volume curve (Fig. 1). As the timing of image acquisition occurred in unison with plethysmograph volume measurements, the lung gas volume when speckle first appeared in the image could be determined. The total lung gas volume minus the ADS volume provided an estimate of gas volume within the terminal air sacs. The ADS volume was subtracted from the lung gas volume, and the area under the curve (above the ADS volume) was calculated over three inflations (from inflation onset to inflation onset) at inflations 5 and 20 and every

20th inflation for 120 inflations. The time the lung gas volume exceeded the ADS volume was calculated over three inflations and expressed as a percentage of the total duration of the three inflations.

Results are presented as means ± SE. A *P* value of <0.05 was considered statistically significant. Student unpaired *t*-tests were used to compare differences between groups. Changes in FRC, V_T, alveolar gas volume, and duration above ADS volume per inflation over time were analyzed using a two-way repeated-measures ANOVA with a Fishers least significant difference post hoc test.

RESULTS

Animal data. Sixteen preterm pups (from 8 rabbits) were ventilated from birth: eight with 0PEEP and eight with 5PEEP. The gestational age (28.1 ± 0.1 vs. 28.3 ± 0.2 days) and mean pup weight (35.3 ± 1.1 and 33.8 ± 2.6 g) were similar in both groups. Four pups were excluded (2 per group) from ADS volume analyses due to synchronization problems between image acquisition and plethysmograph recording. The calculated ADS volume was similar in 0PEEP (2.5 ± 0.8 ml/kg) and 5PEEP (3.0 ± 0.3 ml/kg) pups.

PCI of lung aeration. Movies of lung aeration were constructed by compiling the PC X-ray images sequentially (at ~1.5 × normal speed) and demonstrate the beneficial effect of PEEP on lung aeration from birth. (The online version of this article contains supplemental data: *movies 1* and *2*.) In the absence of PEEP (*movie 1*), although air eventually entered and aerated the distal gas exchange regions of the lung, the lungs did not retain gas at end expiration for at least the first 120 inflations. Numerous inflations were required before air reached the terminal airways, but the air only remained briefly in the terminal airways during inflation (Fig. 2). During expiration, most airways either collapsed or refilled with liquid in 0PEEP pups, so that much of the respiratory tree was unaerated at end expiration (Fig. 2); air could be seen trapped in small conducting airways in some pups. In contrast, the lungs of pups ventilated with 5PEEP (*movie 2*) aerated rapidly, beginning in the large, proximal airways and extending to the distal regions. Lung aeration increased with each inflation, and air was retained in both the distal and larger conducting airways at end expiration, with no evidence of lung collapse or liquid refilling the airways (*movie 2*; Fig. 2). Lung aeration in 5PEEP pups was not uniform, beginning in the apical lobes, particularly the right apical lobe, and followed by aeration of the medial and then basal lobes.

FRC. All pups ventilated without PEEP (0PEEP) failed to accumulate a FRC that exceeded the ADS volume (Fig. 3). FRC in 0PEEP pups increased transiently to 0.9 ± 0.7 ml/kg after the first five inflations, but was significantly reduced by inflations 20 and 40 (*P* < 0.05) and did not significantly differ from zero throughout the remainder of the experiment. As a result, the percentage of time that lung gas volumes were greater than the ADS volume in 0PEEP pups was <20% for the first 40 inflations, remaining below 50% for the first 120 inflations (Figs. 3 and 4B). Thus, without PEEP, lung gas volumes only increased above the ADS volume briefly during, and shortly, after inflation (Fig. 3).

All 5PEEP pups rapidly accumulated a FRC and, at all time points, had a significantly higher FRC than pups ventilated with 0PEEP (*P* < 0.001) (Fig. 4A). The FRC increased rapidly

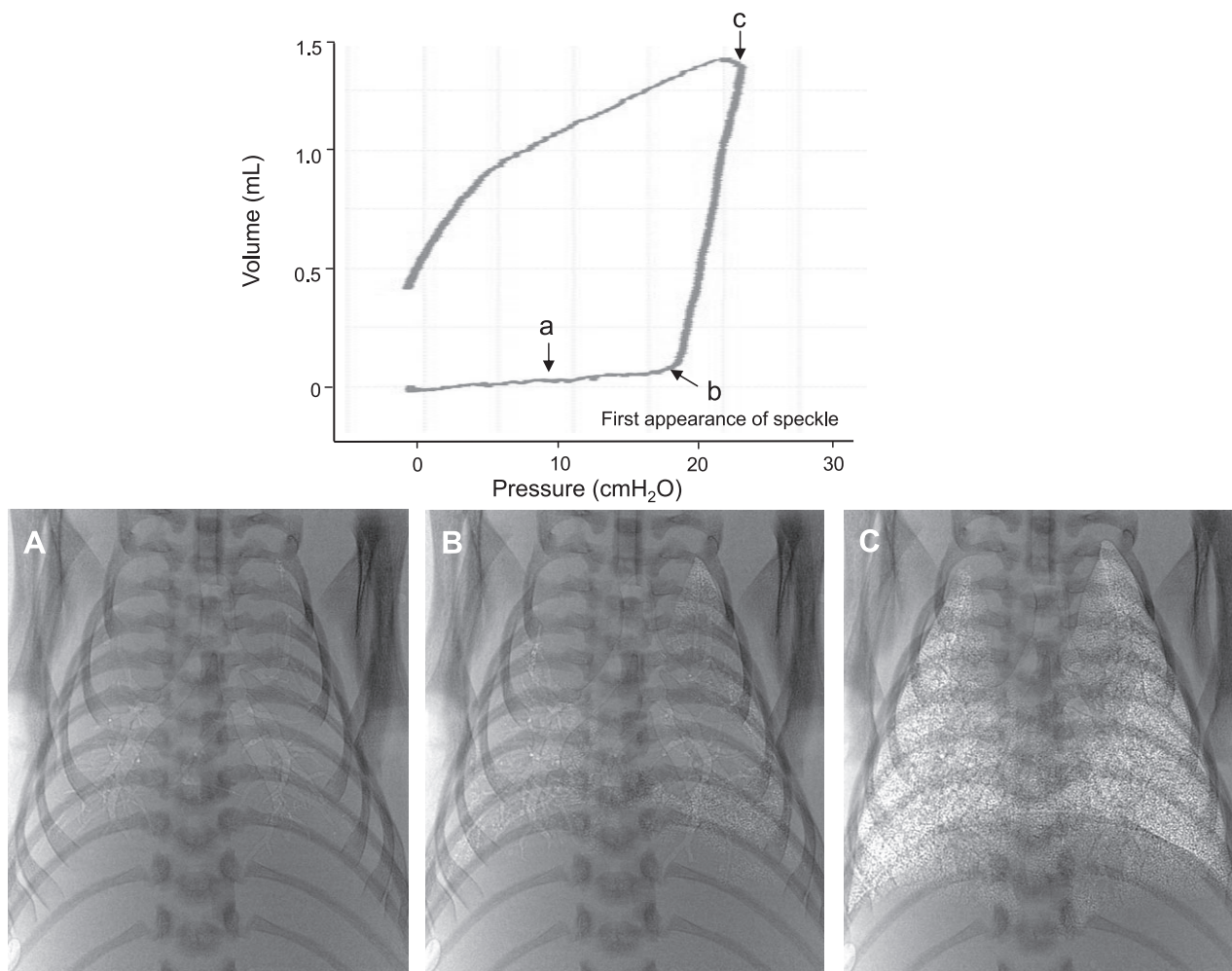


Fig. 1. A pressure-volume (PV) curve of a newborn rabbit pup during its first inflation with air and phase-contrast X-ray images (A, B, C) acquired at different points on the curve (a, b, c, respectively), as indicated by the arrows. Image B was acquired immediately after the point of inflection on the inflation limb of the PV curve and shows aeration just beginning in the distal airways. The lung air volume at this point was taken to be the anatomic dead space volume.

to 8.4 ± 2.4 ml/kg within the first five inflations, to 18.4 ± 1.8 ml/kg by inflation 40 and then remained at this level (Fig. 4A). Thus, in 5PEEP pups, the percentage of time that lung gas volumes were greater than the ADS volumes increased to 100% within the first five inflations, and then the gas volume remained above the ADS volume throughout the respiratory cycle (Fig. 4B).

V_T and lung compliance. The expired V_T in OPEEP and 5PEEP pups significantly increased from the onset of ventilation until the 120th inflation ($P < 0.05$; Figs. 3 and 5A). The increase in expired V_T in 5PEEP pups was less than in OPEEP pups with increasing inflation number. As a result, the mean V_T of OPEEP pups was significantly greater than that of 5PEEP pups after inflation 60 ($P < 0.05$) (Fig. 5A). At this time, the difference in V_T between OPEEP and 5PEEP pups was equal to the FRC in 5PEEP pups, as pups in both groups achieved the same lung gas volume at end inflation (45.7 ± 5.6 vs. 48.2 ± 3.2 ml/kg). However, at end expiration, the lung gas volume was 19.9 ± 3.2 ml/kg in 5PEEP pups and 0.9 ± 0.7 ml/kg in OPEEP pups. Respiratory system compliance increased during lung aeration, but no difference could be detected between the groups (Fig. 5B).

Time-related analysis of gas in the distal airways. The time-dependent restraint on gas exchange was assessed by measuring the percentage of time spent at a gas volume greater than the ADS volume (Fig. 4B; see above) and the time-related integral of the lung gas volume over a three inflation cycle (Fig. 6). The lung gas volume time integral increased rapidly in 5PEEP pups, reaching 36.0 ± 2.7 ml·s·kg⁻¹ at inflation 20, which was significantly greater than in OPEEP pups (6.4 ± 2.0 ml·s⁻¹·kg⁻¹). By inflation 40, the lung gas volume integral had increased further to 44.6 ± 2.6 ml·s·kg⁻¹ in 5PEEP pups and then remained at this level. In contrast, in OPEEP pups, the lung gas volume integral increased from 9.5 ± 2.1 ml·s·kg⁻¹ at inflation 40 to 23.9 ± 4.0 ml·s·kg⁻¹ at inflation 120, which was significantly lower than in 5PEEP pups (Fig. 6).

DISCUSSION

Our study demonstrates that ventilation of preterm rabbit pups from birth with 5PEEP greatly improves liquid clearance and aeration of the distal airways and prevents airway collapse at end-expiration (see movie 2). As a result, pups ventilated with 5PEEP rapidly accumulated an FRC with each inflation

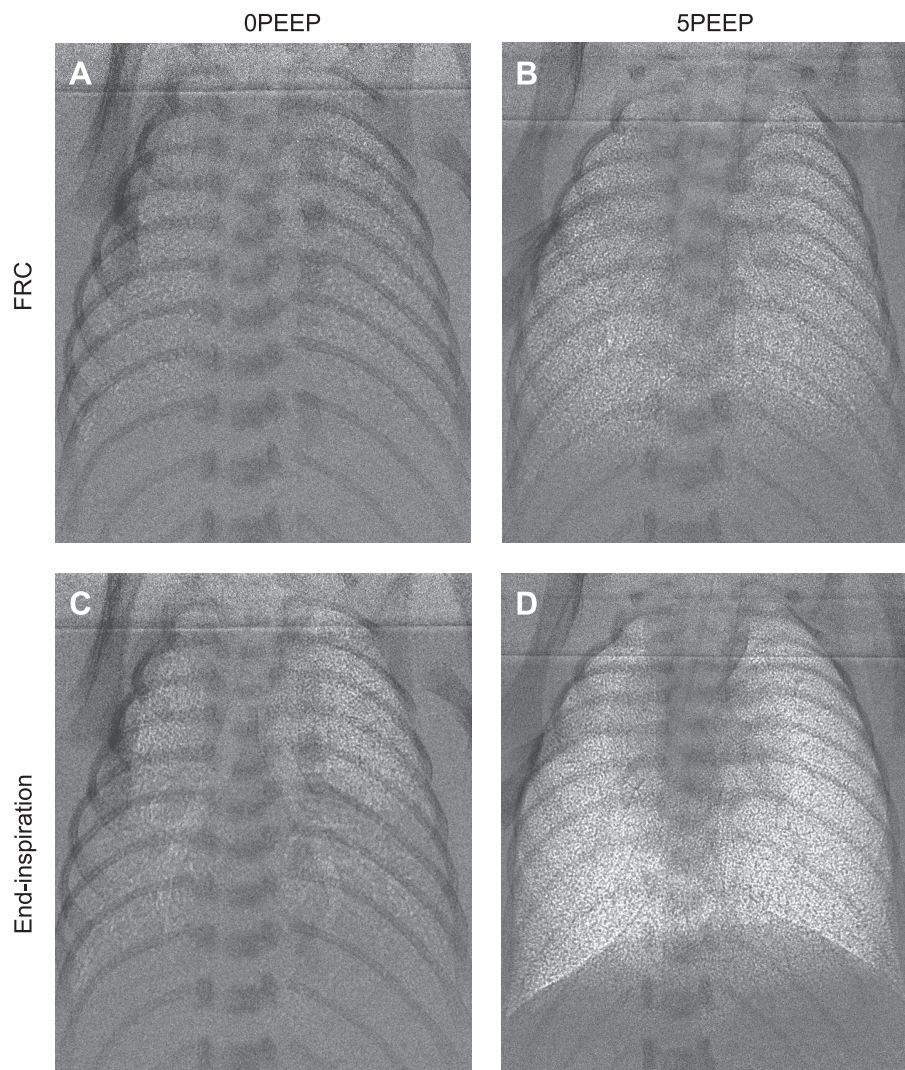


Fig. 2. Phase-contrast X-ray images of preterm rabbit pups ventilated with 0 cmH₂O (0PEEP; *A* and *C*) and 5 cmH₂O (5PEEP; *B* and *D*) of positive end-expiratory pressure (PEEP). Images were acquired at either functional residual capacity (FRC; *A* and *B*) or near end inspiration (*C* and *D*) at approximately the 20th breath after the onset of ventilation.

(increasing to 19.9 ± 3.2 ml/kg), and the distal gas exchange regions remained gas-filled at end expiration. Without PEEP (see *movie 1*), air only penetrated the distal gas exchange regions briefly during inflation, and the airways either partially collapsed or refilled with liquid at end expiration. As these pups were intubated and sedated, these results are most applicable to intubated, apneic newborn, very preterm infants. However, as the application of a continuous positive airway pressure will also maintain a pressure gradient across the airway wall, and thereby facilitate liquid clearance, our results may provide an additional explanation for the beneficial effects of continuous positive airway pressure in very preterm infants.

Airway liquid removal at birth is thought to result from adrenaline-induced activation of amiloride-sensitive sodium channels, which increases sodium reabsorption, thereby creating an osmotic gradient for water uptake across the pulmonary epithelium (12, 24). The liquid is taken up into the interstitial tissue compartment of the lung (3), resulting in a transient increase in interstitial tissue pressure (22), which gradually reduces (over 2–4 h) as the liquid is cleared via the lymphatics and vasculature. As this process matures in late gestation (4, 34), partly due to the action of cortisol (32, 33), this mechanism is unlikely to be active in the immature lung of very

preterm infants. Thus the mechanisms driving airway liquid clearance and lung aeration in these infants are unclear. Our laboratory has recently suggested that transepithelial hydrostatic pressures generated during inspiration provide a hydrostatic pressure gradient for liquid to leave the airways (11). The finding that PEEP facilitates airway liquid clearance and lung aeration in mechanically ventilated pups is consistent with this suggestion and provides further evidence that transepithelial hydrostatic pressures play an important role in this process, particularly in the immature lung.

The phase-contrast X-ray movie sequences demonstrate the positive effect of PEEP on lung aeration in very preterm rabbit pups mechanically ventilated from birth. Although the spatial pattern of lung aeration was not uniform, the extent of lung aeration increased with each inflation, and, once aerated, regions did not collapse or refill with liquid during expiration. These observations were supported by plethysmography measurements, demonstrating that FRC rapidly increased to 19.9 ± 3.2 ml/kg, values similar to that observed in spontaneously breathing term pups (unpublished observations). As a result, after the first five inflations, the lung gas volume remained permanently above the ADS volume, allowing gas exchange to occur throughout the respiratory cycle. Without PEEP, al-

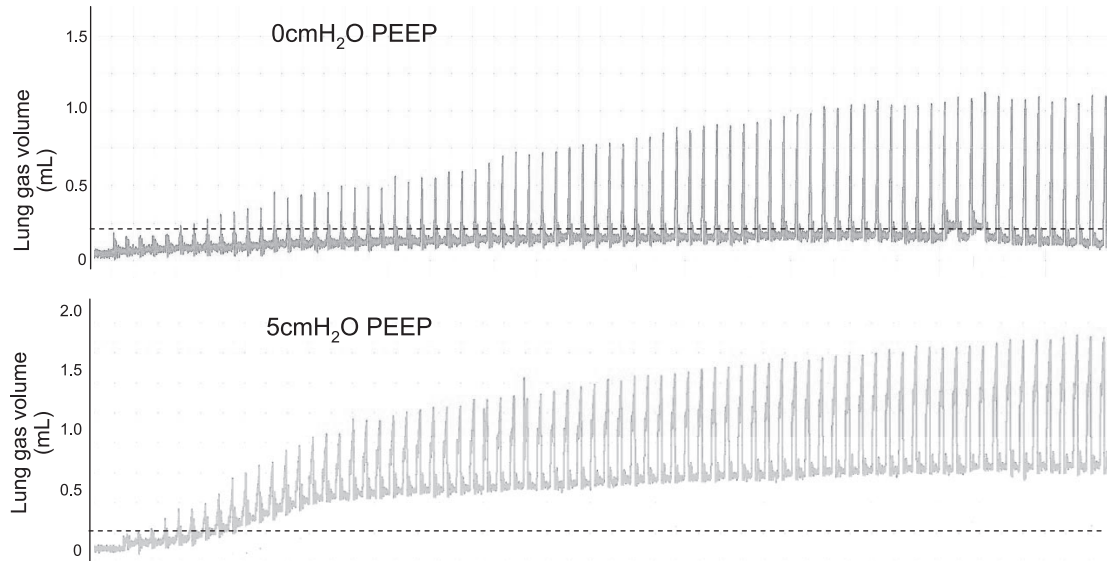


Fig. 3. Lung gas volumes, measured using plethysmography, in preterm rabbit pups ventilated from birth with either 0PEEP (*top*) or 5PEEP (*bottom*). The dotted line represents the calculated anatomic dead space volume. Note that pups ventilated with 5PEEP rapidly established a FRC, whereas pups ventilated in the absence of PEEP (0PEEP) did not develop a FRC.

though gas eventually penetrated into the lung periphery, the phase-contrast X-ray images show that air was not retained in the distal airways and some of their conducting airways, at end expiration (*movie 1* and Fig. 2). These observations are supported by plethysmography measurements, demonstrating that, without PEEP, a FRC greater than the ADS volume (3.0 ± 0.3 ml/kg) could not be formed. As a result, the mean gas volume was greater than the ADS volume for <50% of the time in 0PEEP pups. It is unclear why, in the absence of PEEP, FRC (as measured by plethysmography) tended to decrease below zero, but this was not due to leaks in the plethysmograph. We consider it more likely that lung aeration increased the pup's buoyancy, causing a small upward displacement of the pup; this would have been greater in PEEP pups, but any small reductions in FRC were likely obscured by the larger PEEP-induced increase in FRC.

In the healthy mature lung, gas exchange is not limited by gas diffusion rates and is determined by the thickness and surface area of the air/blood gas barrier (31), as well as partial pressure gradients for O_2 and CO_2 (8). However, in a partially liquid-filled immature lung of a preterm infant, gas diffusion rates are likely to be limited, particularly for O_2 , which is much less diffusible than CO_2 (31). This is because the lung gas barrier is structurally immature, and distal airway collapse at end expiration limits the volume of gas and the time available for alveolar gas exchange. A quantitative analysis of this relationship was assessed by measuring the lung gas volume time integral above the ADS volume. This integral rapidly increased in 5PEEP pups and was much greater than in 0PEEP pups (Fig. 6), because the lung gas volume remained significantly above the ADS volume throughout expiration. Thus the gas exchange potential of the lung, particularly for oxygen, was greater in 5PEEP pups compared with 0PEEP pups for the first 120 inflations after birth. It is possible that the effect of PEEP on increasing blood oxygenation during the newborn period (21, 26, 30) is due to an increase in the gas volume time integral.

After the first 120 inflations, the V_T was greater in 0PEEP pups compared with 5PEEP pups, despite all pups being

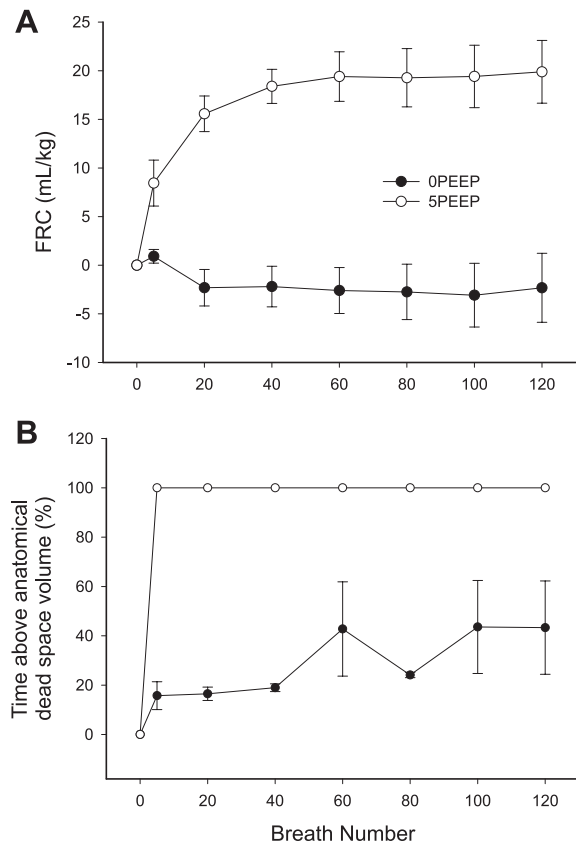


Fig. 4. *A*: the change in FRC with time measured from birth in preterm rabbit pups ventilated from birth with either 0PEEP (●) or 5PEEP (○). *B*: the percentage of time that the lung gas volume remained above the anatomic dead space volume in 0PEEP and 5PEEP pups. For each pup, values were averaged over a 3-breath cycle at breath 5 ± 1 and 20 ± 1 and every 20th breath thereafter.

ventilated with the same PIP. As the volume at peak inflation was similar in both groups, the difference in V_T was due to the higher FRC in 5PEEP pups as lung gas volumes decreased to near zero at end expiration in 0PEEP pups. In addition to the atelectrauma, caused by cyclic lung collapse (13, 25), in the absence of PEEP, a larger V_T could cause greater shear stress and lung injury in 0PEEP pups compared with 5PEEP pups (2). Other studies have shown that PEEP increases lung compliance (23, 27) by shifting lung volume into a more compliant region of the pressure-volume curve. Although the effect of PEEP on lung compliance is not immediate in the partially liquid-filled lung (26), it is possible that the maximum volumes achieved at end inflation in our study were close to the top of the pup's pressure-volume curve. Thus, as 5PEEP pups had a higher FRC, the V_T may have been limited in these pups. It was necessary to ventilate pups with a PIP of 35 cmH₂O, as preliminary experiments demonstrated that lower PIPs were unable to initiate lung aeration, and it was not possible to alter the ventilator settings during imaging.

PCI provides a unique macroscopic view of the lung's transition into a gas-filled organ, demonstrating the importance of PEEP (*movie 1* and *movie 2*). The spatial pattern of lung aeration in preterm pups was different to that of spontaneously breathing term pups. In ventilated preterm pups, the apical lobes aerated first, whereas the medial/basal lobes aerated first

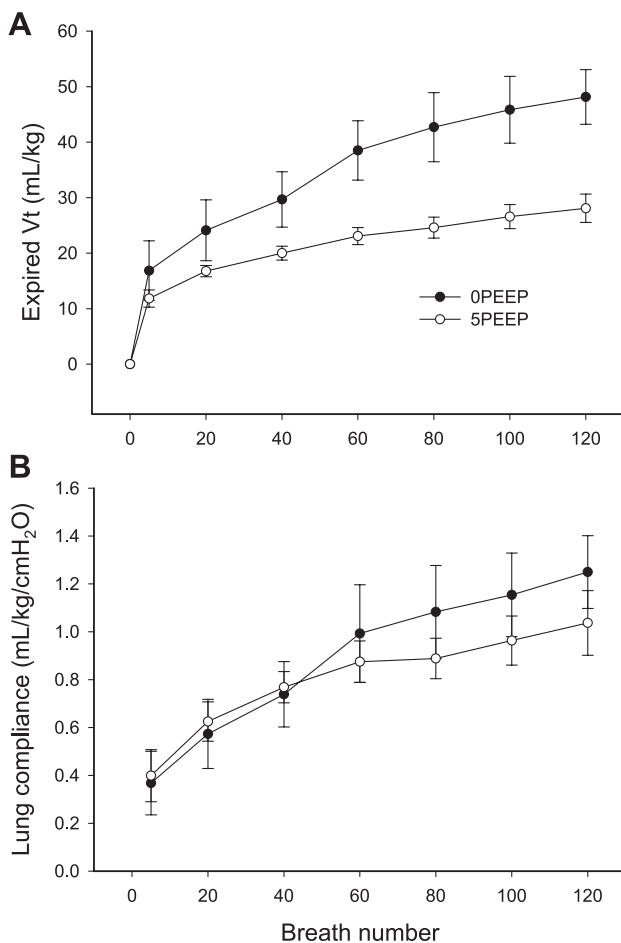


Fig. 5. Increase in tidal volume (V_T ; A) and lung compliance (B) in preterm rabbit pups ventilated from birth with either 0PEEP (●) or 5PEEP (○).

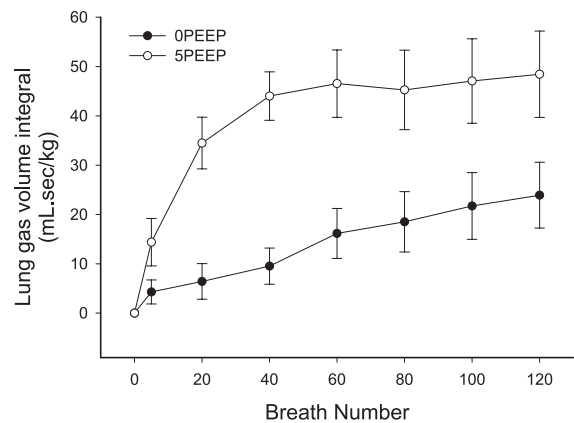


Fig. 6. The lung gas volume time integral (area under the lung gas volume curve) in preterm rabbit pups ventilated from birth with either 0PEEP (●) or 5PEEP (○).

in spontaneously breathing term pups (11, 14). As diaphragmatic contraction drives lung expansion and reductions in airway pressure during spontaneous breathing, it is not surprising that lung aeration begins in the medial/basal regions, particularly as parts of the chest wall deform during spontaneous breathing (11). However, during mechanical ventilation, the application of positive pressure to the airways should provide relatively similar pressure gradients to apical and basal lobes, leading to uniform rates of aeration. As preterm pups were ventilated in an upright position, it is possible that gravity influenced the spatial pattern of lung aeration; however, spontaneously breathing pups were also studied in an upright position (11). It is pertinent to note that, although very preterm human infants are usually ventilated in a horizontal position, and not upright as in this experiment, the effect of PEEP on FRC is independent of body position (unpublished observations).

This study has shown that mechanical ventilation from birth with PEEP improves lung aeration and gas exchange potential of the lung immediately after birth. The phase-contrast X-ray images clearly demonstrate that PEEP prevents distal airway collapse at end expiration, allowing FRC to accumulate and lung aeration to increase with each inflation. These data also provide further evidence to indicate that transepithelial hydrostatic pressure gradients contribute to airway liquid clearance and lung aeration after birth.

GRANTS

This research was supported by the Australian Research Council and the Australian National Health and Medical Research Council. We acknowledge financial support from the Access to Major Research Facilities Programme, which is a component of the International Science Linkages Programme established under the Australian Government's innovation statement, "Backing Australia's Ability." The authors also gratefully acknowledge the support provided by the SPring-8 synchrotron facility (Japan), which was granted by the SPring-8 Program Review Committee (proposal nos. 2006B0002, 2007A0002). A. B. te Pas is a recipient of a Ter Meulen Fund grant for working visits, Royal Netherlands Academy of Arts and Sciences, The Netherlands. M. J. Kitchen is a recipient of an Australian Research Council Post-Doctoral Fellowship.

REFERENCES

1. Barker PM, Gowen CW, Lawson EE, Knowles MR. Decreased sodium ion absorption across nasal epithelium of very premature infants with respiratory distress syndrome. *J Pediatr* 130: 373–377, 1997.

2. Bjorklund LJ, Ingimarsson J, Curstedt T, John J, Robertson B, Werner O, Vilstrup CT. Manual ventilation with a few large breaths at birth compromises the therapeutic effect of subsequent surfactant replacement in immature lambs. *Pediatr Res* 42: 348–355, 1997.
3. Bland RD. Dynamics of pulmonary water before and after birth. *Acta Paediatr Scand Suppl* 305: 12–20, 1983.
4. Brown MJ, Olver RE, Ramsden CA, Strang LB, Walters DV. Effects of adrenaline and of spontaneous labour on the secretion and absorption of lung liquid in the fetal lamb. *J Physiol* 344: 137–152, 1983.
5. Dawes GS. *Fetal and Neonatal Physiology*. Chicago, IL: Year Book, 1968.
6. Dinger J, Topfer A, Schaller P, Schwarze R. Effect of positive end expiratory pressure on functional residual capacity and compliance in surfactant-treated preterm infants. *J Perinat Med* 29: 137–143, 2001.
7. Harding R, Hooper SB. Regulation of lung expansion and lung growth before birth. *J Appl Physiol* 81: 209–224, 1996.
8. Hill EP, Power GG, Longo LD. Mathematical simulation of pulmonary O₂ and CO₂ exchange. *Am J Physiol* 224: 904–917, 1973.
9. Hooper SB, Harding R. Fetal lung liquid: a major determinant of the growth and functional development of the fetal lung. *Clin Exp Pharmacol Physiol* 22: 235–247, 1995.
10. Hooper SB, Harding R. Role of aeration in the physiological adaptation of the lung to air-breathing at birth. *Curr Respir Med Rev* 1: 185–195, 2005.
11. Hooper SB, Kitchen MJ, Wallace MJ, Yagi N, Uesugi K, Morgan MJ, Hall C, Siu KK, Williams IM, Siew M, Irvine SC, Pavlov K, Lewis RA. Imaging lung aeration and lung liquid clearance at birth. *FASEB J* 21: 3329–3337, 2007.
12. Jain L, Eaton DC. Physiology of fetal lung fluid clearance and the effect of labor. *Semin Perinatol* 30: 34–43, 2006.
13. Jobe AH, Hillman N, Polglase G, Kramer BW, Kallapur S, Pillow J. Injury and inflammation from resuscitation of the preterm infant. *Neonatology* 94: 190–196, 2008.
14. Kitchen MJ, Lewis RA, Morgan MJ, Wallace MJ, Siew MLL, Siu KKW, Habib A, Fouras A, Yagi N, Uesugi K, Hooper SB. Dynamic measures of lung air volume using phase contrast X-ray imaging. *Phys Med Biol* 53: 6065–6077, 2008.
15. Kitchen MJ, Lewis RA, Yagi N, Uesugi K, Paganin D, Hooper SB, Adams G, Jureczek S, Singh J, Christensen CR, Hufton AP, Hall CJ, Cheung KC, Pavlov KM. Phase contrast X-ray imaging of mice and rabbit lungs: a comparative study. *Br J Radiol* 78: 1018–1027, 2005.
16. Kitchen MJ, Paganin D, Lewis RA, Yagi N, Uesugi K. Analysis of speckle patterns in phase contrast images of lung tissue. *Nucl Instrum Methods Phys Res A* 548: 240–246, 2005.
17. Kitchen MJ, Paganin D, Lewis RA, Yagi N, Uesugi K, Mudie ST. On the origin of speckle in x-ray phase contrast images of lung tissue. *Phys Med Biol* 49: 4335–4348, 2004.
18. Lewis RA, Hall CJ, Hufton AP, Evans S, Menk RH, Arfelli F, Rigon L, Tromba G, Dance DR, Ellis IO, Evans A, Jacobs E, Pinder SE, Rogers KD. X-ray refraction effects: application to the imaging of biological tissues. *Br J Radiol* 76: 301–308, 2003.
19. Lewis RA, Yagi N, Kitchen MJ, Morgan MJ, Paganin D, Siu KK, Pavlov K, Williams I, Uesugi K, Wallace MJ, Hall CJ, Whitley J, Hooper SB. Dynamic imaging of the lungs using x-ray phase contrast. *Phys Med Biol* 50: 5031–5040, 2005.
20. McCann UG, Schiller HJ, Carney DE, Gatto LA, Steinberg JM, Nieman GF. Visual validation of the mechanical stabilizing effects of positive end-expiratory pressure at the alveolar level. *J Surg Res* 99: 335–342, 2001.
21. Michna J, Jobe AH, Ikegami M. Positive end-expiratory pressure preserves surfactant function in preterm lambs. *Am J Respir Crit Care Med* 160: 634–639, 1999.
22. Miserocchi G, Poskurica BH, Del Fabbro M. Pulmonary interstitial pressure in anesthetized paralyzed newborn rabbits. *J Appl Physiol* 77: 2260–2268, 1994.
23. Nilsson R, Grossmann G, Robertson B. Artificial ventilation of premature newborn rabbits: effects of positive end-expiratory pressure on lung mechanics and lung morphology. *Acta Paediatr Scand* 69: 597–602, 1980.
24. Olver RE, Walters DV, Wilson M. Developmental regulation of lung liquid transport. *Annu Rev Physiol* 66: 77–101, 2004.
25. Polglase GR, Hillman NH, Pillow JJ, Cheah FC, Nitsos I, Moss TJM, Kramer BW, Ikegami M, Kallapur SG, Jobe AH. Positive end-expiratory pressure and tidal volume during initial ventilation of preterm lambs. *Pediatr Res* 64: 517–522, 2008.
26. Probyn ME, Hooper SB, Dargaville PA, McCallion N, Crossley K, Harding R, Morley CJ. Positive end expiratory pressure during resuscitation of premature lambs rapidly improves blood gases without adversely affecting arterial pressure. *Pediatr Res* 56: 198–204, 2004.
27. Schlessel JS, Susskind H, Joel DD, Bossuyt A, Harrold WH, Zanzi I, Chanana AD. Effect of PEEP on regional ventilation and perfusion in the mechanically ventilated preterm lamb. *J Nucl Med* 30: 1342–1350, 1989.
28. Suzuki Y, Yagi N, Uesugi K. X-ray refraction-enhanced imaging and a method for phase retrieval for a simple object. *J Synchrotron Radiat* 9: 160–165, 2002.
29. Verma RP. Respiratory distress syndrome of the newborn infant. *Obstet Gynecol Surv* 50: 542–555, 1995.
30. Vilstrup CT, Bjorklund LJ, Larsson A, Lachmann B, Werner O. Functional residual capacity and ventilation homogeneity in mechanically ventilated small neonates. *J Appl Physiol* 73: 276–283, 1992.
31. Wagner PD. Diffusion and chemical-reaction in pulmonary gas-exchange. *Physiol Rev* 57: 257–312, 1977.
32. Wallace MJ, Hooper SB, Harding R. Regulation of lung liquid secretion by arginine vasopressin in fetal sheep. *Am J Physiol Regul Integr Comp Physiol* 258: R104–R111, 1990.
33. Wallace MJ, Hooper SB, Harding R. Role of the adrenal glands in the maturation of lung liquid secretory mechanisms in fetal sheep. *Am J Physiol Regul Integr Comp Physiol* 270: R1–R8, 1996.
34. Walters DV, Ramsden CA, Olver RE. Dibutyryl cAMP induces a gestation-dependent absorption of fetal lung liquid. *J Appl Physiol* 68: 2054–2059, 1990.
35. Yagi N, Suzuki Y, Umetani K, Kohmura Y, Yamasaki K. Refraction-enhanced x-ray imaging of mouse lung using synchrotron radiation source. *Med Phys* 26: 2190–2193, 1999.